



PATIENT
Norma Kastella

SPECIES
Canine

BREED
American
Staffordshire Terrier
Mix

SEX
Female Spayed

AGE
1 year

WEIGHT
64lbs

INTERPRETED BY
Maggie Machen
Lamy, DVM, DACVIM
(Cardiology)

IMAGING PERFORMED BY
Jenna Walsh, CVT

HOSPITAL NAME
VCA Mckenzie
Animal Hospital

REFERRING VET
Dr. Kastella

INVOICE
22551

DATE
2/14/22

NORMAL PARAMETER	4.5-5.5	<2.7	1.3	<1.6	28-40	40-100	<0.6
PATIENT	NA	2.0	1.4	1.3	26	50	NM
CANINE CARDIAC PARAMETERS	HR (BPM)	AV VMAX (m/s)	PV MAX (m/s)	BODY WEIGHT (kg)	LA 2D short axis Base view (cm)	LVIDd Avg; 2D and m- mode short axis (cm)	LVIDs Avg; 2D and m- mode short axis (cm)
NORMAL PARAMETER	50-100	0.7-1.7	0.7-1.6	BELOW	BELOW	BELOW	BELOW
PATIENT	116	1.8	1.4	29.0	2.5	4.7	3.5
*Normal chamber parameters expressed as a mean value (SD)				3	1.27 (5.3)	2.46 (2.46)	1.36 (5.5)
BODY WEIGHT DEPENDENT PARAMETERS				5	1.40 (4.5)	2.74 (5.2)	1.60 (4.7)
Adapted from June Boon, Veterinary Echocardiography, 1998 Rishniw M and Hollis NE, J Vet Intern Med 2000; 14:429-435 Hansson et al, Vet Rad and Ultrasound 2002 Bonagura et al. Echocardiography: principles of interpretation, Vet Clin North Am 15:1177, 1995				10	1.50 (3.8)	3.27 (3.5)	2.06 (3.1)
				15	1.83 (2.0)	3.71 (2.4)	2.43 (2.1)
				20	2.02 (1.9)	4.14 (2.2)	2.80 (2.0)
				25	2.18 (2.4)	4.48 (2.9)	3.10 (2.5)
				30	2.33 (3.3)	4.83 (3.9)	3.39 (3.4)
				35	2.48 (4.3)	5.17 (5.0)	3.69 (4.5)
				40	2.62 (5.2)	5.48 (6.1)	3.96 (5.4)
	50	2.88 (7.1)	6.07 (8.3)	4.46 (7.4)			

INTERPRETATION OF THE FINDINGS & FURTHER RECOMMENDATIONS

Overtly normal cardiac dimension and function. The only cause of a murmur identified is borderline increased flow velocity through the LVOT/aortic root. No obvious subaortic ridge or valvular abnormalities are visualized, and in the absence of structural abnormalities this is considered a benign flow murmur. If this is a new murmur, it is reasonable to monitor periodically via recheck echocardiography in the future. Trace/mild MR and TR are identified which may reflect early valve disease or may be physiologic in origin. Follow up is advised. Finally, the LV function is borderline depressed which is suspected to be due to reportedly heavy sedation. No additional issues identified.

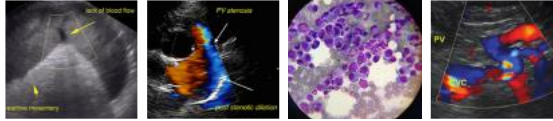
The ECG shows a profound respiratory sinus arrhythmia with occasional blocked P waves. The prolongation of the PR interval supports high vagal tone as the cause of these findings (Wenkebach), and this is largely benign. Again these findings are suspected to be due to sedation, rather than a primary issue. Follow up may be indicated should the resting heart rate be reportedly low in the future.

No structural or arrhythmic explanation for the anesthetic event identified here. Consider a drug reaction or alternative explanation.

No cardiac medications are indicated. From a cardiac standpoint, there is no cardiac contraindication for general anesthesia.

Monitor for any development of cough, labored breathing or exercise intolerance.

Recommend recheck echocardiogram in 12-18 months to screen for progression or development of concurrent cardiac disease that the preexisting murmur may mask.



PATIENT

Norma Kastella

SPECIES

Canine

BREED

American
 Staffordshire Terrier
 Mix

SEX

Female Spayed

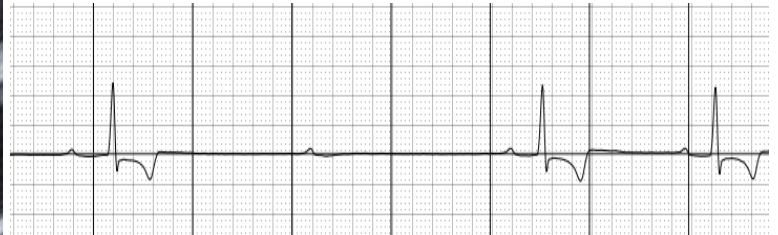
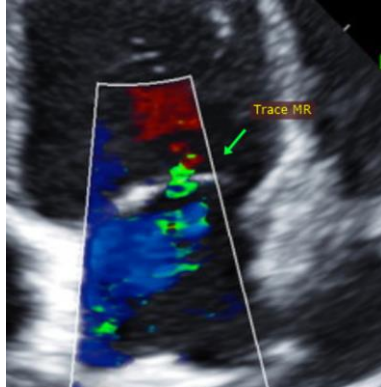
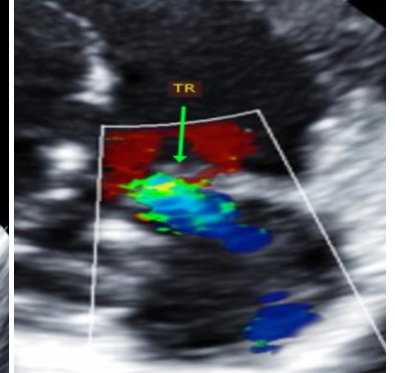
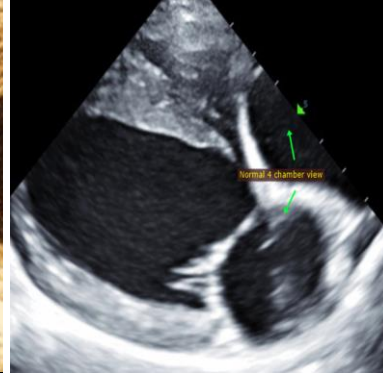
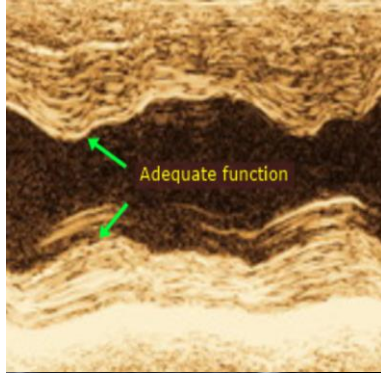
AGE

1 year

WEIGHT

64lbs

IMAGES



INTERPRETED BY

Maggie Machen
 Lamy, DVM, DACVIM
 (Cardiology)

IMAGING PERFORMED BY

Jenna Walsh, CVT

HOSPITAL NAME

VCA Mckenzie
 Animal Hospital

REFERRING VET

Dr. Kastella

INVOICE

22551

DATE

2/14/22

The information and recommendations provided are based on the images presented by the referring veterinarian. No evaluation can be communicated regarding pathology that was not visible in the image/video clips provided.

Thank you for this referral. This report was generated using transcription software, and minor dictation errors may be present. If the clinical or image interpretation does not parallel your findings or if I can be of any further assistance, please contact me.

Maggie Machen Lamy, DVM
 Diplomate of the American College of Veterinary Internal Medicine (Cardiology)
 info@sonopath.com